

# Oxygen-Ozone Therapy for Local Adipose Deposits and Oedematous Fibrosclerotic Panniculopathy

M.A. SIRITO

*Fisiomedical; Genova*

**Key words:** lipodystrophy, ozone, lipolysis

**SUMMARY** - Localised adipose tissue deposits and oedematous fibrosclerotic panniculopathy are different conditions but they often coexist in the same areas. They both respond to treatment with an appropriate concentration of oxygen-ozone as the gas mixture has a lipolytic effect and regulates tissue irroration. This accounts for the use of  $O_2-O_3$  in the initially oedematous stages of panniculopathy whereas there is currently no scientific evidence for its use for fibrinolysis. This study proposes a treatment protocol based on five years' experience of specific  $O_2-O_3$  treatment for these conditions.

## Introduction

Among the many fields of application of oxygen-ozone therapy in aesthetic medicine, two conditions are convincing from the standpoint of scientific rationale and efficacy: localised adipose tissue deposits and oedematous fibrosclerotic panniculopathy (OFSP), commonly known as cellulite. Local adipose deposits do not constitute a disease and may occur anywhere and vary in quantity. Instead, cellulite is a qualitative dystrophic change in the adipose panniculus localised exclusively in the limbs and due to changes in the microcirculation.

The two conditions often coexist in the same area, accounting for difficulties in diagnosis and treatment. Ozone has lipolytic properties<sup>1</sup>, binding to the double carbon bonds in fatty acids, promoting scission and elimination. The lipolytic effects have already been demonstrated by magnetic resonance imaging (*Rivista Italiana di Ossigeno-Ozonoterapia* 1: 87-92, 2002).

It has been demonstrated<sup>2,3,4,5</sup> that all the morphopathogenic events in OFSP result from impaired capillary-venular permeability with slowing of the local microcirculatory haemodynamics. As ozone enhances both the deformability of red blood cells and<sup>2,3</sup> DPG levels and hence tissue irroration<sup>6</sup>, its use appears to be appropriate in the initial, mainly oedematous, stages of OFSP.

Since ozone has no proven fibrinolytic effect, there is currently no indication for its use in the advanced fibrotic stages of OFSP. On the other

hand, since localised and lipodystrophic adipose deposits may coexist in the same area<sup>7</sup>, it is not illogical to expect therapeutic results (reduction in volume due to lipolysis) also in the mainly fibrotic areas.

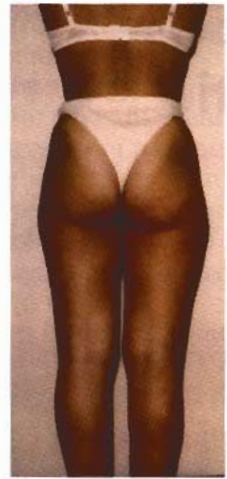This paper describes five years' personal experience of  $O_2-O_3$  infiltration to treat localised adipose tissue deposits and OFSP from March 2001 to February 2006.

## Materials and Methods

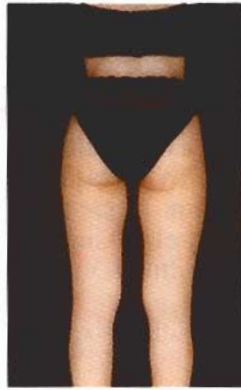A medical ozone device equipped with photometric control of ozone concentration was used (Mod. Ozofutura - Alnitic). Ozone concentration was set at 5  $\mu\text{g/ml}$ , and 10 ml of gas mixture were injected for every 5 cm area to be treated at a variable depth of between 10 and 20 mm. Treatment was administered weekly or twice weekly for ten sessions for each therapeutic cycle and two or more cycles a year. The gas mixture was injected using 50 cc eccentric cone syringes and 27 G needles from 13 to 19 mm long inserted at an angle of 90° for local adipose deposits and almost tangential down to the subcutaneous region in the mainly lipodystrophic areas.

The following treatment exclusion criteria were adopted:

- Pathological processes in the areas to be treated.
- Coagulation disorders likely to cause prolonged bleeding.
- Frequent faintness or hypotension.



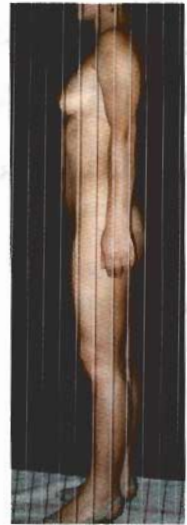A



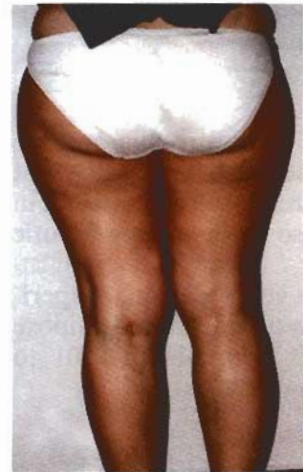B



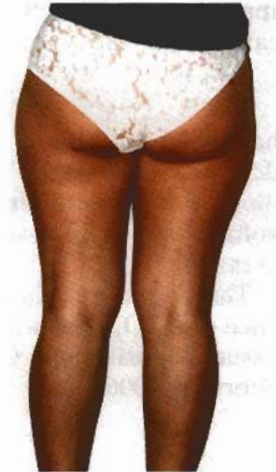C



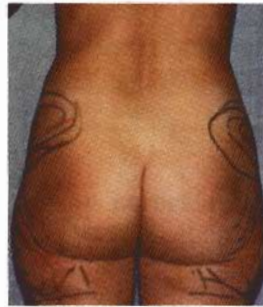D



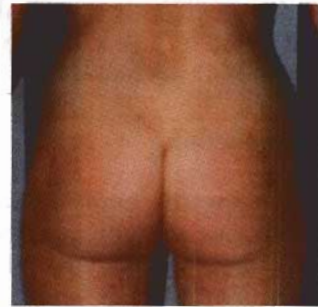E



F

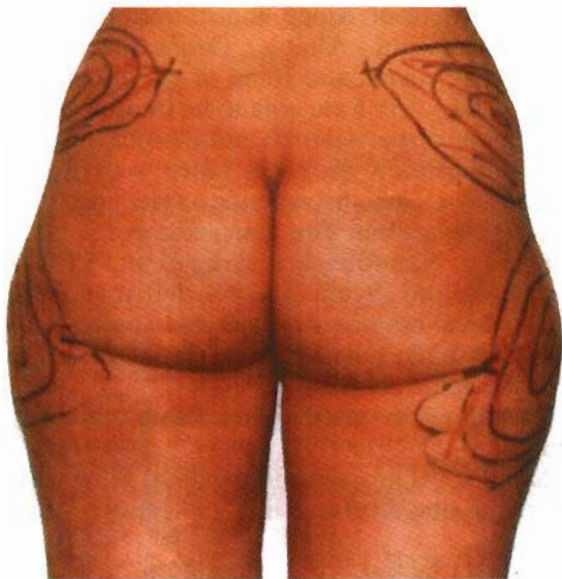

G

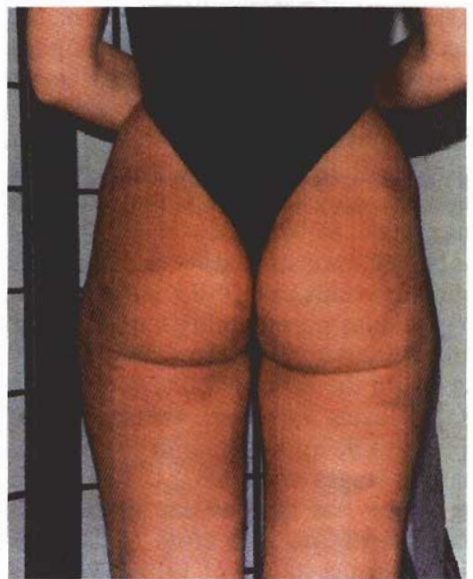


H

Figure 1 Five subjects before and after oxygen-ozone therapy at concentrations of 5 mcg/ml. The results were obtained after a number of weekly or twice weekly treatment sessions varying from 10 to 30.



I



J

- Tendency to put on weight.
- Neurosis and psychosis.
- Underage without written parental consent.
- Pregnancy and breastfeeding.

Treatment was applied to the hips, the periumbilical area, the thighs in lateral view of the femur trochanters and the proximal medial thigh region, the knee above the kneecap and the projection of the medial condyles of femur and tibia, and the extensor region of the arms. Anthropometric measurements (weight, fat mass, plicometry and circumference of the area to treat) were taken before, during and after the treatment cycles.

Overweight or frankly obese patients were put on a slimming diet and told to exercise regularly. Subjects who failed to lose weight were invited to suspend the treatment. The following side effects were observed:

- Pain and burning sensation lasting seconds.
- Reddening lasting minutes.
- Haematomas.
- Perception of gas beneath the skin lasting minutes.

- Attenuated sense of heaviness in the legs lasting days.

## Results

The reduction in thickness of the dystrophic and normal adipose layer documented by the anthropometric measurements was most pronounced in the arms, hips, periumbilical area, proximal medial thigh region, the area above the kneecap and the medial knee region, and less evident in the trochanters. Non responders were fewer than 15%.

## Conclusions

Oxygen-ozone therapy is an effective means of treating local adipose tissue deposits and cellulite. The results observed indicate that the greater the reactive fibrotic component of cellulite, the less effective the treatment is at the concentrations used. Our findings await further confirmation with future applications of oxygen-ozone therapy in this field.

## References

- 1 Bocci V: 'Ossigeno-ozonoterapia', Casa Ed. Ambrosiana 2000: 73-82.
- 2 Curri SB: Lymphoedeme et cellulite, *J. Med. Esth* 10: 11-19, 1982.
- 3 Curri SB: Stasi venosa e liposclerosi: aspetti morfofunzionali, Proc. VII Riun. Fiorentina Angiologia, Firenze 1990: 74-75.
- 4 Curri SB: L'interessamento del microcircolo cutaneo, adiposo e muscolare nella stasi venosa cronica degli arti inferiori, in *Flebologia*, vol. I. Salus Ed. Int., Roma 1988: 31-41.
- 5 Curri SB: Correlazioni microvascolo-tessutali e stasi venosa: alterazioni dei microvasi e dei tessuti cutaneo, adiposo e muscolare, in *Flebologia* 87, Monduzzi Ed., Bologna 1987: 265-284.
- 6 Bocci V: Ossigeno-ozonoterapia, Casa Ed. Ambrosiana 2000: 83-97.
- 7 Bartoletti CA: Mesoterapia, in: A. Rituffo e C.A. Bartoletti: *La cellulite*, Salus Ed. Int., Roma 1983: 79-83.

Dr M.A. Sirito  
 Fisiomedical  
 Via XX Settembre, 23  
 16121 Genova  
 Italy  
 E-mail: mario.sirito@libero.it